

CONDYLOMAS

in men

Treatment guidance



CONDYLOMAS

Condylomata acuminata, also known as condylomas or genital warts, are benign warts located in the anogenital area.

In uncircumcised men, condylomas most frequently occur on the head of the penis, on the corona of the glans, on the frenulum and on the inside of the foreskin. In circumcised men, condylomas most frequently occur on the shaft of the penis.⁷

Condylomas rarely occur in the oral cavity or the conjunctiva of the eyes.³

More than 90% of condyloma cases are caused by human papillomavirus (HPV) genotypes 6 and 11^{1,2}, and condylomas are considered the most common sexually transferred disease in the Western world with a transmission rate of 60% between partners. The high transmissibility of condylomas is due to the thin mucous membrane surface, which is more susceptible to infection.¹⁴

Among men, the prevalence is largest for men in the 25-29 age group.⁴ In addition, the prevalence of condylomas is higher among smokers.⁷ The cure rate is lower for men than for women.¹

Condylomas may materialise as individual warts, several warts together or coalesced tumour-like elements. There are most frequently 5-15 elements in the same area with a diameter of 1-5 mm.⁷

Condylomas vary in appearance and will appear as moist on the mucous membrane with a “cauliflower-like” surface. On dry and possibly hairy skin, the condylomas will appear more solid and keratinised, particularly in teenagers

and young adults.³ The colour of a condyloma may vary from pink to salmon and from white/greyish white to different shades of brown (pigmented elements). Condylomas tend to be non-pigmented, but in some cases appear pigmented on the shaft of the penis in the groin, perineum and in the perianal area.⁷

Treatment of condylomas must be considered symptomatic. Condylomas can cause itching and, for larger condylomas, maceration, irritation, pain and bleeding.⁷ Treatment will remove visible skin changes, but condylomas are a subclinical infection with an incubation time of 3 weeks to 8 months, which means that there is a risk of recurrence after treatment.^{3,7} For the same reason, patients with condylomas should be treated as soon as possible to break the infection chain and reduce the infection of others.



What is Hydrozid®

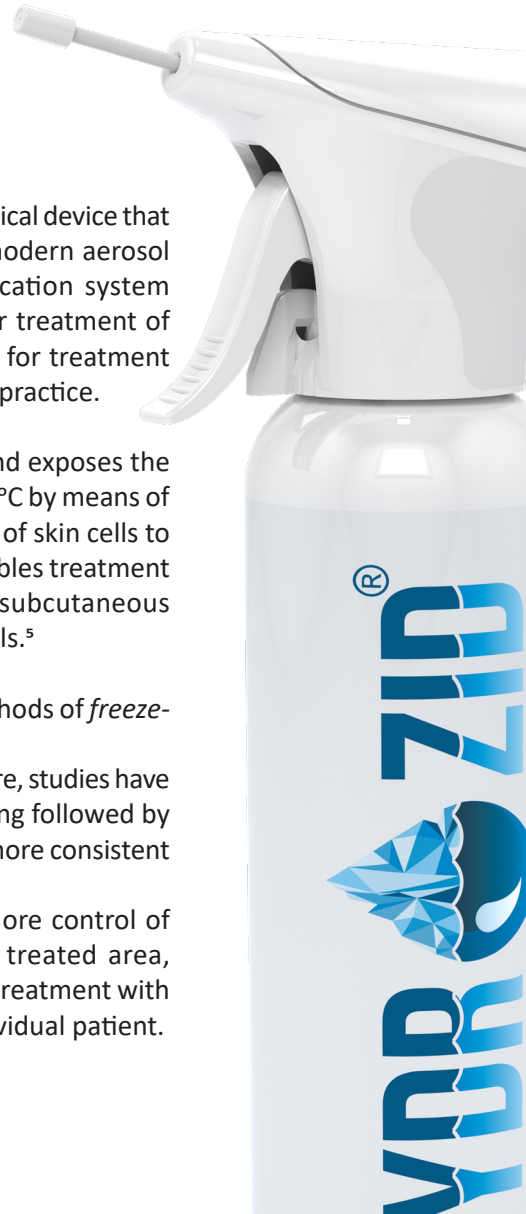
Treatment

Precautions and contraindications

Disposal of Hydrozid®

What is Hydrozid®

- ▶ Hydrozid® is an innovative CE-marked medical device that combines traditional cryosurgery with modern aerosol technology. Its patented, unique application system provides a safe and effective method for treatment of condylomas. Hydrozid® is also approved for treatment of an additional 10 indications in clinical practice.
- ▶ Hydrozid® contains the gas norflurane and exposes the condyloma to temperatures as low as -54°C by means of a concentrated jet.² The varying reaction of skin cells to the low temperatures of cryosurgery enables treatment of epidermal cells without damaging subcutaneous connective tissue, fibres and immune cells.⁵
- ▶ Hydrozid® treatment is based on the methods of *freeze-thaw cycles* and *temperature control*. Rather than continuous treatment exposure, studies have shown that repeated exposures to freezing followed by thawing (a freeze-thaw cycle) result in a more consistent and effective treatment.⁶ These cycles also afford the therapist more control of the temperature and its effect on the treated area, which helps prevent overtreatment.⁶ All treatment with Hydrozid® should be adapted to the individual patient.



What is
Hydrozid®

Treatment

Precautions and
contraindications

Disposal of
Hydrozid®

Inform the patient before treatment

Provide the patient with the Hydrozid® patient instructions.

You can request the patient instructions free of charge from the Hydrozid® customer service by e-mail: info@hydrozid.eu

Treatment of individual condylomas

Even though condylomas most frequently occur as 5-15 elements in the same area, individual condylomas may also occur.

Application template

When treating individual condylomas, use one of the accompanying application templates to protect the surrounding healthy tissue. The application templates have holes in 6 different sizes (3-10 mm in diameter).

When treating condylomas, it is advisable to apply treatment to the actual condyloma and on a small margin of healthy tissue surrounding the condyloma.⁷ The recommended width of the margin varies depending upon the procedure of clinical trials and clinicians' experiences, but a margin of 1 mm is often advised.

You should therefore use the hole in the application template that covers the condyloma and a margin of healthy tissue

surrounding the condyloma.

During application, the treatment margins may be blurred due to formation of ice crystals, which means that the template may also help focus on the actual size of the condyloma during treatment.

You can also use the application templates' size indications to compare the size of the condyloma after each procedure to assess the effect of treatment.

The application templates can be used to treat more condylomas on the same patient, after which they must be discarded.



application template

What is
Hydrozid®


Treatment

Precautions and
contraindications

Disposal of
Hydrozid®

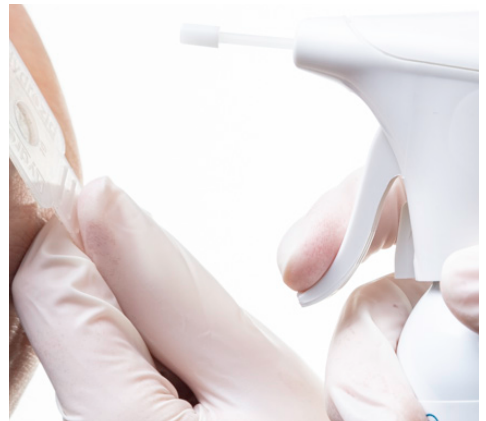Treatment steps

After unpacking – do not remove the tip of the application tube. It must remain in place during treatment.

1. Release the locking mechanism under the activation arm, from left to right. The canister is now ready to use.
2. Hold the application template in place above the condyloma with your non-dominant hand.



Hold the Hydrozid® canister in your dominant hand, as vertically as possible. Push lightly on the canister until you hear a hissing noise and the gas is released. If you push the canister too hard, the sound will be more like when dispensing a deodorant spray, which releases unnecessary amounts of gas with a risk of damaging surrounding healthy tissue. Also, this is not an economical use of the gas.

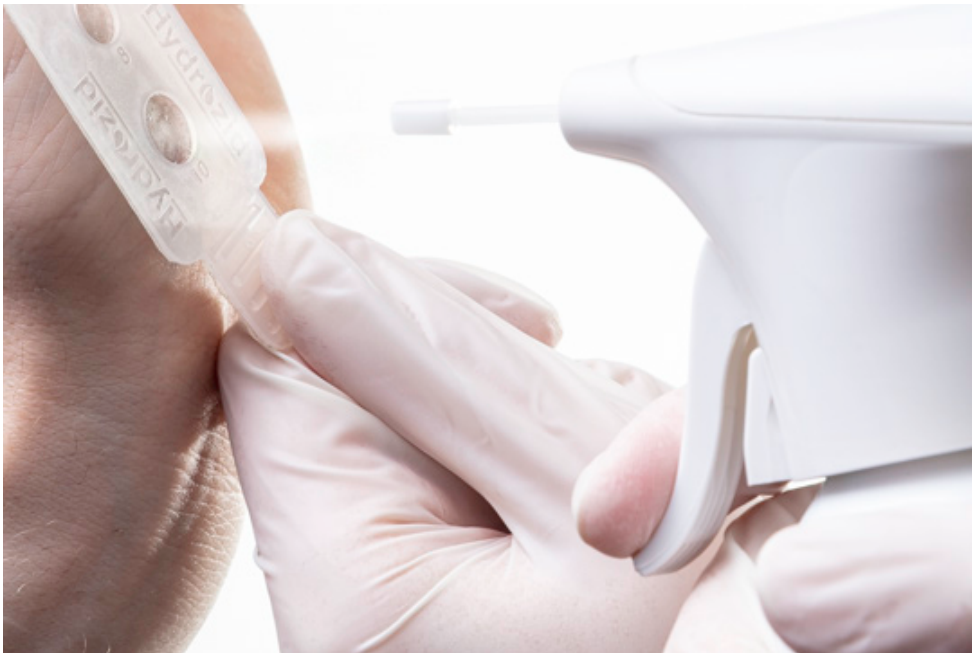

What is
Hydrozid®

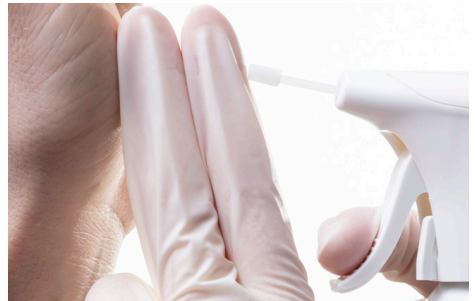Treatment

Precautions and
contraindications

Disposal of
Hydrozid®



3. Spray at a distance of 2-3 centimetres from the condyloma, for up to 6 seconds. A film of white ice crystals will now form in the treated area. After (up to) 30 seconds, the ice crystals are no longer white, indicating that the thawing period has ended. The first freeze-thaw cycle is now completed.



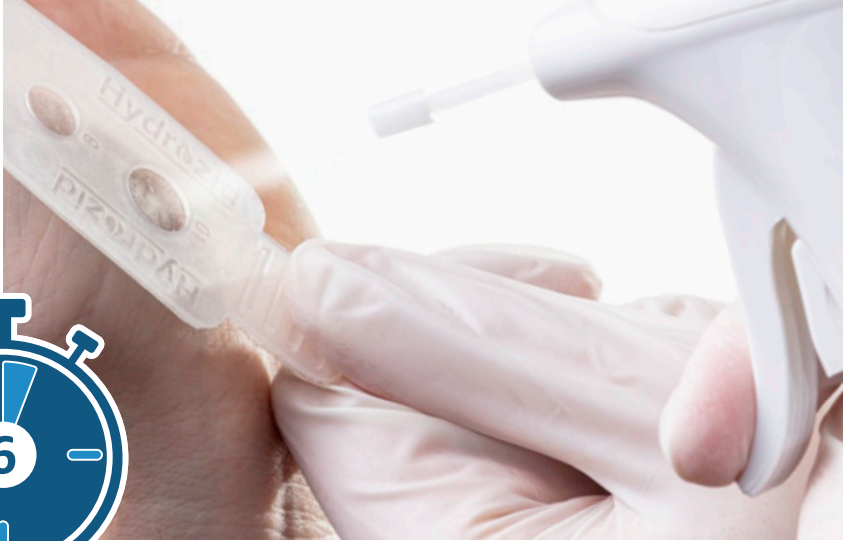2-3 centimetres from the condyloma

What is Hydrozid®

Treatment


Precautions and contraindications

Disposal of Hydrozid®



4. Then repeat another freeze-thaw cycle. The recommended number of freeze-thaw cycles is 2-6 cycles. The total treatment time is between 12-36 seconds.

The therapist assesses the patient and the treated area between each freeze-thaw cycle and must regard the treatment times as recommendations. Treatment for a longer period than recommended is associated with more frequent and more intense side effects.¹⁰



What is
Hydrozid®

▼
Treatment

Precautions and
contraindications

Disposal of
Hydrozid®

Treatment of individual, sporadically located condylomas

Condylomas may occur individually, but sporadically dispersed from each other, for instance several individual condylomas in several locations on the scrotum. In such cases, the treatment can be streamlined, as it is possible to treat 2-4 condylomas within the same period of time as it takes to treat one (2 x 6 seconds - 6 x 6 seconds).

Prepare the canister and locate the application template as described in treatment steps 1 and 2 in the above-mentioned section.

Next treatment steps:

1. Spray at a distance of 2-3 centimetres from the first condyloma, for up to 6 seconds. While the ice crystals thaw and the thawing period passes, continue treating the second condyloma.
2. Treat the second condyloma using the same procedure. While the ice crystals thaw and the thawing period passes for condylomas 1 and 2, continue treating the third condyloma.
3. Treat the third condyloma using the same procedure. While the ice crystals thaw and the thawing period passes for condylomas 1, 2 and 3, continue treating the fourth condyloma.
4. Finish by treating the fourth condyloma for 6 seconds using the same procedure.

When the thawing period for the fourth condyloma has passed, the first freeze-thaw cycle is complete. Now you can start a new freeze-thaw cycle on the first condyloma, followed by the three others. Treat each condyloma with a total of 2-6 freeze-thaw cycles, equating to 12-36 seconds of treatment of each condyloma.

What is
Hydrozid®

Treatment

Precautions and
contraindications

Disposal of
Hydrozid®

Treatment of several condylomas located in the same area


In cases where several condylomas are located in the same area as coalesced elements, treat the condylomas synchronously.

Treatment steps

After unpacking – do not remove the tip of the application tube. It must remain in place during treatment.

1. Release the locking mechanism under the activation arm, from left to right. The canister is now ready to use.
2. Hold the Hydrozid® canister in your dominant hand, as vertically as possible. Push lightly on the canister until you hear a hissing noise and the gas is released. If you push the canister too hard, the sound will be more like when dispensing a deodorant spray, which releases unnecessary amounts of gas with a risk of damaging surrounding healthy tissue.
3. Spray at a distance of 2-3 centimetres from the collective centre of the condylomas and continue by constant spraying in circular motions over the limit of the outermost condylomas in the area to include a margin of 1 mm of healthy tissue surrounding the condylomas. A film of white ice crystals will now form in the treated area. All of the condylomas, including the margin, must be covered by the ice crystals. After (up to) 30 seconds, the ice crystals are no longer white, indicating that the thawing period has ended. The first freeze-thaw cycle is now completed.
4. Then repeat another freeze-thaw cycle. The recommended number of freeze-thaw cycles is 2-6 cycles. The total amount of time for treating the treated area must not exceed 36 seconds.

The therapist assesses the patient and the treated area between each freeze-thaw cycle and must regard the treatment times as recommendations. Treatment for a longer period than recommended is associated with more frequent and more intense side effects.¹⁰



What is
Hydrozid®


Treatment

Precautions and
contraindications

Disposal of
Hydrozid®

Side effects, healing process and treatment outcome

Cryosurgery therapy may cause a stinging or burning sensation during treatment.

The treated area may appear red, tender and swollen immediately after treatment.

Within 24 hours after the completion of treatment, inflammation develops in response to the cell death. This process contributes further to destroying the condylomas⁹ and is thus a natural reaction in the inflammatory phase of the wound healing process.

Wounds and blisters may subsequently occur in the treated area.⁸

After treatment, the patient must keep the treated area clean by washing it daily with water and non-perfumed soap, mornings and evenings.

The patient should refrain from sexual intercourse until the treated area has been completely treated and fully healed. To avoid recurrence or new cases of condylomas, current partners should also be examined for condylomas, and sexual abstinence is advised among the partners until the treatment of all condylomas has finished.¹²

When treating hair-bearing areas, cryosurgery may cause alopecia areata in rare cases.⁹

The recommended treatment interval after the first treatment is one week¹¹ but should always be adjusted to the individual patient.

The number of treatments depends on the patient's individual clinical response and is assessed by the therapist.

What is
Hydrozid®

Treatment

▼
**Precautions and
contraindications**

Disposal of
Hydrozid®

Precautions and contraindications

Hydrozid® should only be used by trained healthcare professionals.


- Even though the effect of short freezing times as recommended in this material does not result in scarring¹³, Hydrozid® must be used with care to avoid damaging the dermis.

Exercise special caution when applying Hydrozid®:

- near cutaneous nerves, tendons.
- in persons with impaired arterial or venous circulation⁸ (e.g. diabetes patients).
- in persons with thin and/or sensitive skin (e.g. elderly with ageing skin, systemic scleroderma, persons treated with inhaled steroids for a prolonged period of time, etc.)
- on persons with dark skin types in whom hypo- or hyperpigmentation may occur⁸
- in hair-bearing areas to avoid the risk of alopecia areata

Do not use Hydrozid®:

- on open skin lesions or eczematous skin to avoid subcutaneous emphysema⁹
- in patients with cryoglobulinemia, Raynaud's disease, cold urticaria and blood dyscrasias and Pyoderma gangrenosum¹³
- in case of uncertain diagnosis of the type of lesion (biopsy for skin carcinoma)¹³
- on healthy skin



What is
Hydrozid®

Treatment

Precautions and
contraindications

**Disposal of
Hydrozid®**

Disposal of Hydrozid®

The Hydrozid® canister may be disposed of as normal household waste.

**IF YOU HAVE ANY QUESTIONS OR, CONTRARY TO
EXPECTATIONS, EXPERIENCE CHALLENGES WHEN
USING HYDROZID®**

Please contact customer service by e-mail: info@hydrozid.eu

NOTES

Hydrozid® was developed by the Danish-owned family enterprise BIBAWO Medical A/S, Denmark, and is currently used in several countries around the world.

Hydrozid® is also approved for the following therapeutic indications: acrochordon, actinic keratosis, cervical contact bleeding, condyloma acuminatum, gingival melanin hyperpigmentation, seborrheic keratosis, lentigo, molluscum contagiosum, verruca plana, verruca plantaris and verruca vulgaris.

Learn more about Hydrozid® on www.hydrozid.eu or by contacting our customer service by e-mail: info@hydrozid.eu

References

1. European Course on HPV associated pathology: guidelines for primary care physicians for the diagnosis and management of anogenital warts. Krogh G von, Lacey CJN, gross G, Barrasso R, Schneider A Sex Transm Inf 2000; 76:162-168
2. Anbefalinger om forebyggelse, diagnose og behandling af seksuelt overførbare infektioner. SST 2015
3. Kondylomer – Odense lokalt. Localised 11.01.2020 on: Kondylomer - Odense lokalt - sundhed.dk
4. Patel H, Wagner M, Singhal P et al. Systematic review of the incidence and prevalence of genital warts. BMC Infectious Diseases 2013;13:39
5. Graham GF, Tuchay SM. 2016. Therapeutic Principles and Techniques in a W. Abramovits et al. (eds.), Dermatological Cryosurgery and Cryotherapy. Springer-Verlag London 2016. Chapter 32.
6. Sharma VK, Khandpur S. Guidelines for cryotherapy. Indian J Dermatol Venereol Leprol 2009;75(Suppl 2):90-100. Received: August 2008. Accepted: October 2008
7. Lacey CJ, Woodhall SC, Wikstrom A et al. 2012 European guideline for the management of anogenital warts. J Eur Acad Dermatol Venereol 2013;27:e263-70.
8. Sterling J.C et. al 2014, British Association of Dermatologists' guidelines for the management of cutaneous warts 2014. British Journal of Dermatology. 2014, pp. 696–712
9. Thai, K-E & Sinclair, R. D., 1999. Cryosurgery of benign skin lesions. Australasian Journal of Dermatology, 1999, 40, pp: 175-186
10. Lipke, M. 2006, An Armamentarium of Warts Treatments. Clinical Medicine & Research. Volume 4, number 4: 273-293
11. Larsen, H. K., & Kofoed, K. 2018. Kondylomer er mere end en benign tilstand. Ugeskrift for læger. 2018;180:V01180031
12. Rasi, A., Soltani-Arabshahi, R., & Khatami, A. (2007). Cryotherapy for anogenital warts: factors affecting therapeutic response. Dermatology Online Journal, 13(4).
13. Andrews, M. D. 2004. Cryosurgery for Common Skin Conditions. AMERICAN FAMILY PHYSICIAN. Volume 69, number 10 / May 15, 2004, pp. 2365-2372
14. Eassa, B. I et. al. 2011. Intradermal injection of PPD as a novel approach of immunotherapy in anogenital warts in pregnant women. Dermatologic Therapy, vol 24, 2011, 137-143.